

A Prospective Study of Non-Surgical Primary Rhinoplasty Using a Polymethylmethacrylate Injectable Implant

ALEXANDER RIVKIN, MD*

BACKGROUND Nonsurgical rhinoplasty involves the use of injectable fillers to improve the contours of the nose. It has become a widely practiced procedure since this author first popularized it in 2003. The use of permanent fillers in nonsurgical rhinoplasty has not been well documented, especially in this country.

OBJECTIVES To demonstrate the safety and effectiveness of a polymethylmethacrylate (PMMA)-based filler for nonsurgical rhinoplasty.

METHODS AND MATERIALS Eligible subjects underwent up to three injection sessions with a commercially available PMMA product and were followed for 1 year. Efficacy was assessed according to evaluator grading of subjects and digital image analysis of standardized photographs.

RESULTS Nineteen subjects were enrolled and followed to conclusion. Average improvement in global score was more than one point observed on day 90 and lasting through 1 year. Eight of 10 subjects showed improvement according to digital image analysis at 1 year. Subject satisfaction was high throughout the study. Adverse events were minimal and well tolerated.

CONCLUSION Filler rhinoplasty using a PMMA-based injectable filler is safe and effective. This is the first study documenting the use of PMMA for this indication. Longer-term follow-up is needed to demonstrate persistence of improvement.

This study was supported by a grant from Suneva.

Surgical rhinoplasty remains one of the most popular facial aesthetic procedures, with more than 100,000 performed annually in the United States.¹ However, surgical rhinoplasty is not without risk, expense, and significant recovery time.² Increasingly, patients who are concerned about risk or cannot afford the price or recovery time are seeking alternatives to surgery as they pursue aesthetic improvement.³

Dermal filling agents have been available in the United States since the 1980s.⁴ The Food and Drug Administration (FDA) indication for most of these fillers is the correction of nasolabial folds and now lip augmentation, yet they are commonly used for off-label facial treatments, including tear trough correction, cheek augmentation, and filling in acne

scars. Over the last few years, filler rhinoplasty has joined this list.

Filler rhinoplasty is the use of dermal filling agents instead of surgery to correct cosmetic defects and improve the contours of the nose. Corning and Gersuny first described injecting filler to correct saddle nose deformity in the late 1800s. They used paraffin, which was effective at first, but was ultimately abandoned due to severe complications.^{5,6} As the FDA has approved new fillers, physicians have again become interested in correcting cosmetic nasal defects nonsurgically.⁷⁻⁹ This author popularized the use of temporary fillers for rhinoplasty in this country in 2003. The use of dermal filling agents in the nasolabial folds and lips has been well characterized, whereas their use in

*Division of Dermatology, Department of Medicine, David Geffen School of Medicine, University of California at Los Angeles, Los Angeles, California

nasal cosmesis has been reviewed only in case studies and small series.^{10–13} The use of a safe, permanent filling agent for nonsurgical rhinoplasty has not been described.

Polymethylmethacrylate (PMMA) has been used in medicine for more than 50 years.¹⁴ Its use as a dermal filling agent has spanned several decades and a number of formulations. Initially marketed outside the United States as a powder to supplement traditional fillers, the first formulation of PMMA microspheres suspended in a carrier was known as Arteplast/Artecoll. These were never commercially available in the United States and were supplanted by a refined formulation known as ArteFill (Suneva Medical, Santa Barbara, CA) (PMMA-collagen) containing a limited range of microsphere sizes.^{15,16} This product contains PMMA in microspheres varying from 30 to 50 μm in diameter and suspended in bovine collagen, water, and lidocaine (for anesthesia). It was U.S. FDA approved in 2006 for nasolabial fold correction.¹⁷ Nonsurgical rhinoplasty using PMMA-collagen may allow long-term benefit without the risks or recovery time. A prospective study was conducted to demonstrate the safety and efficacy of PMMA-collagen in rhinoplasty.

Inclusion and Exclusion Criteria

Subjects were eligible for enrollment if they were aged 18 to 70 and had at least a mild (grade 2) nasal defect as determined by an expert grader using a global nasal defect grading scale from 0 to 4 (see below). Subjects were excluded if they were pregnant or breastfeeding; had a history of keloid or hypertrophic scar formation; had used nonpermanent fillers within the prior 12 months or had ever used a permanent filler or implant; had a history of allergy to meat, collagen, bovine products, or PMMA-collagen ingredients or other severe allergies; had a history of prior autoimmune disease; or had a history of immunosuppression within the last 3 months.

Materials and Methods

An institutional review board approved the study protocol and informed consent form before subjects were enrolled. All subjects underwent an informed consent process before any study activities. The study was conducted in accordance with Good Clinical Practices that have their origins in the Declaration of Helsinki (revised, Seoul, Korea, 2008).

During the induction visit, subjects were administered an intradermal test for allergy to bovine collagen as specified by the instructions for use of the product.¹⁸ After a minimum of 28 days with no positive reaction, each subject underwent injection of the study material. Before injection, photographs were taken and anesthetic cream (20% lidocaine, 6% benzocaine, 4% tetracaine) was applied to the nose for 30 minutes. The subject was placed in the upright position, the anesthetic cream was removed, and the areas were cleansed using isopropyl alcohol. Study material was injected using the 26-G, 5/8-inch needles packaged with the product. Aliquots were injected into the subdermal plane, using a short linear threading technique, with a maximum of 0.05 mL of material injected at each injection point. Threads of material were oriented diagonally to the vertical axis of the nose. In this way, the implant was placed in the deeper and the more-superficial planes. After implantation, the material was manually molded to achieve the desired contour. Corrections were made to the radix, dorsum, alar crease, lateral sidewalls, supratip, and tip regions as needed. After injections, subjects were instructed to resume their normal skin care routine, avoid vigorous exercise for 72 hours, and avoid heavy eyewear for 1 week. Subjects rated their pain on a scale from 0 to 4.

Subjects were injected at days 0 and 30. At day 60, subjects who did not require further injections according to the injecting physician were considered optimally treated. Subjects who required additional injections at day 60 were considered optimally

treated at day 90. All subjects were seen at days 180 and 360 in follow-up.

Assessments

Two live assessments of nasal appearance were used to assess efficacy: a global score (GS) and an improvement score (IS). Standardized photographs were taken at each visit for digital image analysis. The GS is a scale from 0 to 4 indicating increasing degrees of nasal deformity. No comparison with prior appearance or photographs was used when performing the GS. The IS is a 0- to 5-point scale of improvement comparing live subject appearance with baseline photographs; lower scores indicate greater degrees of improvement. (A score of 0 indicates complete correction). The GS was assessed at baseline and all follow-up visits, whereas the IS was performed only at follow-up visits after all injections were completed. The injecting physician and a blinded evaluator physician performed the assessments. Details of these various scales are listed in Table 1.

Along with the assessments described above, subjects performed their own assessment of satisfaction using a 0- to 4-point scale. Subjects viewed their pretreatment photographs and compared their live appearance at each visit after reaching their optimal correction to determine their own satisfaction score.

TABLE 1. Global Score and Improvement Score Scales

<i>Grade</i>	<i>Description</i>
Global score	
0	Defect totally corrected
1	Minimal nasal defect
2	Mild nasal defect
3	Moderate nasal defect
4	Severe nasal defect
Improvement score	
0	Completely corrected
1	≥90% corrected
2	89–75% corrected
3	74–50% corrected
4	49–25% corrected
5	<25% corrected

At each follow-up visit, subjects were queried about changes in health status and any changes were tabulated as adverse events. The implant sites were also evaluated at each follow-up visit for the presence of erythema, nodularity, swelling, or pain and tenderness on a scale from 0 to 4 (absent, trace, mild, moderate, or severe).

Photography

A stereotactic positioning device and standardized lighting and exposure settings were used in obtaining photographic images. At day 0, optimal correction day, and day 360, frontal and profile images of the face were obtained, with special attention to the nasal features.

The digital image analysis process used the profile view of each subject to assign a numerical value to the degree that the nasal dorsum deviated from a straight line in each image. For this analysis, an ideal straight line was plotted onto each subject image from the radix to the nasal tip. This line was compared with the nasal profile in the image and the number of pixels corresponding to the nasal profile that extended beyond that ideal line was tabulated. Thus, greater numbers of pixels indicate a greater deviation from the ideal straight line.¹⁹ Baseline images were compared with day 360 images and the percentage decrease (or increase) in the number of pixels was calculated. An example of this plotted line and assessment is shown in Figure 1.

Results

Nineteen subjects aged 26 to 56 were enrolled (12 female, seven male; 63% female). The injecting and the evaluating physician graded almost all subjects as having a GS of 2, with single subjects having GSs of 1 and 3. Thus the average GS for all enrolled subjects was 2. Fifteen of the 19 enrolled subjects underwent three injection sessions, three had two injection sessions, and one had one injection session. The average volume of implant material injected was 0.46 mL for the first injection session, 0.38 mL for

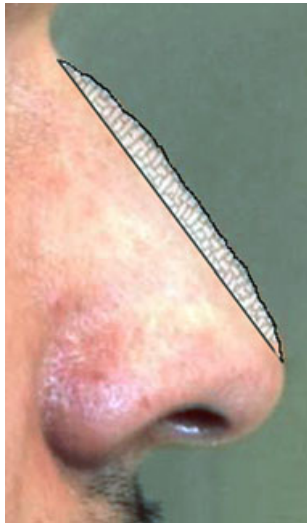


Figure 1. Digital image analysis. The subject’s dorsal nasal profile on the right and the ideal, straightline contour on the left border the highlighted area. The highlighted area represents pixels counted to obtain an area value.

the second injection session, and 0.20 mL for the final injection session. The average total volume of material injected was 0.98 mL.

Efficacy

The scoring by each assessor showed dramatic correlation, with 88% of all scores being identical

and no scores differing by more than 1 grade. Thus, the data for each of the assessments are presented as the average for both evaluators.

Change in subjects’ GS over the course of the study is shown in Figure 2. All subjects had improvement in their GSs. The average GS dropped from two to 0.53 and remained low at 0.66 through day 360. At day 360, six of the 19 subjects had a GS of zero, and 10 subjects had a score of 1 (minimal nasal defect). The poorest day-360 result was a score of 2 (mild nasal defect), assessed by one investigator for a subject whose initial score was 3. Examples of a GS change from 2 to 0 are shown in Figure 3.

ISs strongly mirrored the findings for GSs. At day 90, the average IS was 0.53, with nine of 19 subjects achieving a score of 0 (complete correction) and the remaining ten subjects with a score of 1 (≥90% corrected). By day 360, the average IS had risen to 0.71, with five subjects at 0, 12 subjects with a score of 1 or less, and two subjects with an average score of 1.5. A summary of each of the subject’s scores and findings is shown in Table 2.

The photographs of 10 subjects were judged to be technically adequate to undergo digital image

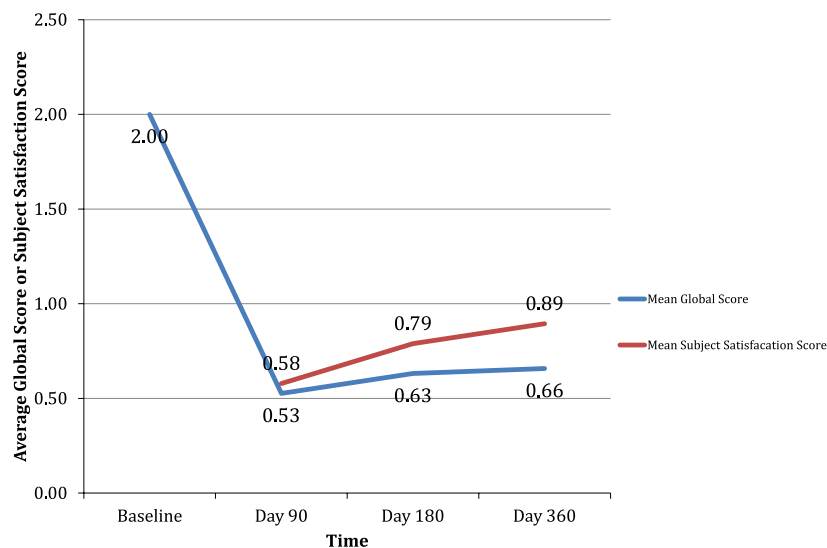


Figure 2. Average global and subject satisfaction scores for all subjects at each time point during the study. The injector and expert blinded physician scores are averaged for each subject.

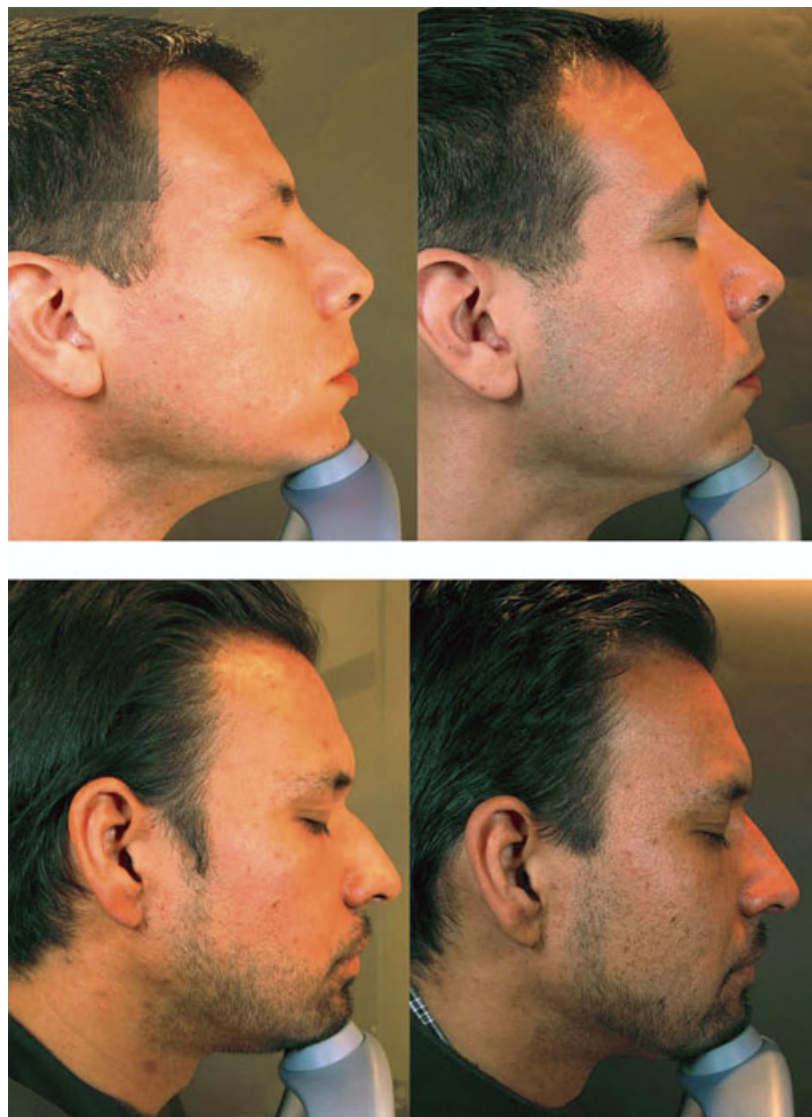

Figure 3. Two representative subjects before treatment and at day 360. The baseline photographs are on the left, and the day-360 images are on the right. Note the improvement in dorsal nasal contour and tip projection. Subject at top was injected with 1.05 mL of polymethylmethacrylate (PMMA)-collagen into the radix, tip, and dorsum over three sessions. Subject at the bottom injected with 1.25 mL of PMMA-collagen to tip and radix over three sessions.

analysis. Eight subjects showed improvement in the day-360 image analysis from the baseline image (average change 28%), although two subjects showed a slight increase in the number of pixels (average 18%). Subjects averaged 19% improvement in the number of pixels outside of the ideal nasal contour.

Average subject satisfaction scores ranged from 0.58 at day 90 to 0.89 at day 360. Across all time points,

86% of subject responses for satisfaction scores were 0 or 1 (very satisfied or satisfied), with the rest being somewhat satisfied.

Safety

The local effects of the study treatment were generally mild and short-lived. The average treatment-related pain score was 1.58 for all areas other than the nasal tip and 2.38 for tip injections. Most

TABLE 2. Summary of Findings for Each Participant

Subject	Age	Prior Rhinoplasty	Baseline Global Score	Areas Injected	Injection Sessions, n	Total Volume Injected, mL	Pain Score (Nontip)	Pain Score (Tip)	12-Month Global Score	12-Month Improvement Score	12-Month Satisfaction Score	Improvement According to Digital Image Analysis, %
1	30	No	2	R, D, T,	3	0.9	1	4	1	1	1	-2.2
2	36	Yes	2	R, D, T	3	1.05	1	1	0	0	0	47.8
3	29	No	2	R, D, T	3	0.9	1	3	1	1	2	N/D
4	28	Yes	2	SW, T	2	0.45	0	2	1	1	1	34.3
5	28	No	2	R, D, T	3	1.45	1	1	1	1	2	N/D
6	32	No	2	R, D, SW, T	3	1	1.5	2.5	0	0	1	N/D
7	38	No	2	R, SW, T	3	1.2	0	0	1	2	3	N/D
8	36	No	2	R, T	3	1.25	0	2	1	1	1	3.2
9	28	No	2	R, D, T	3	1.95	0	2	1	1	1	-33.0
10	52	No	2	R, SW, T	3	1	2	3	1	1	1	N/D
11	28	No	3	R, D, T	3	1.8	1	2	1	1	0	10.0
12	47	No	2	R, D, T	3	0.6	0	2	1	1	1	N/D
13	43	No	2	R, SW, T	3	1.05	0	1.5	0	1	1	39.2
14	56	Yes	2	R, D, SW, T	3	0.65	0	4	0	0	0	N/D
15	26	No	2	R, SW, T	3	0.5	n/a	n/a	1	1	0	41.0
16	29	No	2	R, T	3	1.25	1.5	1.5	1	1	1	N/D
17	31	Yes	2	S, W, T	2	0.45	0	2	0	0	0	20.3
18	37	No	2	R, D, T	1	0.35	1.5	4	0	0	1	31.4
19	33	No	1	R, D, T	2	0.85	2	3	1	1	0	N/D

D, dorsum; n/a, not available; N/D, not done; R, radix; SW, sidewall; T, tip. A single subject (15) did not provide pain data. Pain scores are the maximum for the subject during the study. Where digital image analysis was not performed, the photographs were of insufficient quality to perform the analysis.

subjects experienced pain only with tip injections. No subjects required pain medication after injections. Three subjects were noted to have palpable, but nonvisible, nontender nodules ranging from 1 to 2 mm in size during the post-treatment period. Two of the nodules responded to massage and were absent by the next visit. The final nodule (2 mm) was reported from day 60 through day 360, was nonvisible, did not change in size, and was felt to be consistent with ectopic implant material. The subject did not desire any additional treatment of this finding. There were no signs of persistent implant-induced inflammatory conditions (erythema, swelling, tenderness) in or around the implantation sites. No medical or surgical intervention was required to manage any treatment area adverse events during the study.

Discussion

Injectable PMMA filler can be a safe and effective means to correct nasal contour irregularities. All subjects achieved a GS of minimal deformity or better (grade 0 or 1) by day 90. The improvement was long lasting, with minimal changes in global or ISs by day 360.

Although the use of live grading of subjects remains the most commonly used scoring system for aesthetic treatments, work continues on more-objective measures.²⁰ For this study, a digital image analysis technique was developed using the lateral profile images of subjects' noses. Of the 10 subjects available for analysis, eight demonstrated significant improvement 1 year after treatment. Two subjects did not improve according to this analysis, mostly because their cosmetic defect did not involve the lateral nasal profile.

Most subjects underwent three injection sessions and thus had multiple opportunities for injection-related events. Despite this, subjects had little in the way of swelling, redness, nodularity, or other adverse events. Pain was sometimes notable around the time of injection (especially if the nasal tip was injected)

but never in the postprocedure period. Nodularity was infrequent and well tolerated. Most importantly, no infections, embolization or vascular occlusive events, hypersensitivity reactions, or granulomas were seen.

This point deserves emphasis. A number of case reports of major tissue necrosis and blindness secondary to dermal filler injection have been published. These are rare but devastating events that are usually caused by intra-arterial injection of product. In the case of blindness, the product is thought to enter the ophthalmic circulation by forceful retrograde injection through branches of the dorsal nasal artery. This author has performed more than 500 of these procedures with PMMA-collagen without encountering necrosis or ophthalmic complications. Physicians performing this procedure should be well versed in the techniques to avoid embolic catastrophe, including injecting small amounts of product at a time, injecting using only slight force, injecting only upon withdrawal while the needle is moving, and using multiple smaller treatment sessions rather than a single extensive one.²¹ Figure 4 illustrates the arterial circulation around the nose. All major vessels arise from the nasolabial fold area or more laterally. Confining the

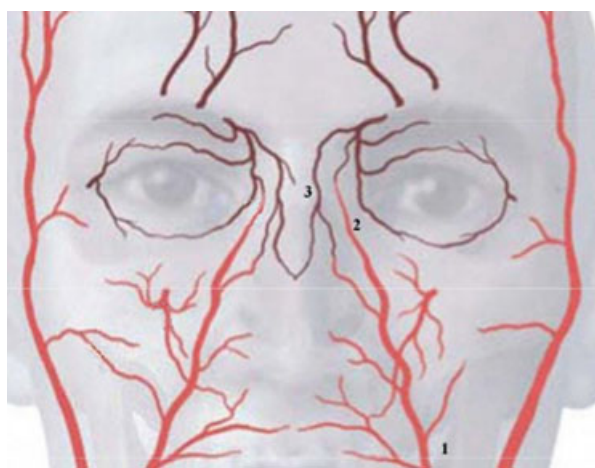


Figure 4. Nasal arterial anatomy. The facial artery (1), angular artery (2), and dorsal nasal artery (3) are shown. Most vessels are well lateral of the midline, creating a safe zone for injection.

injections to the midline (dorsum, radix, and tip) will further reduce the opportunity for an embolic event. Additional caution should be used in patients with previous rhinoplasty because some protective anastomoses within the external carotid circulation may have already been compromised by prior surgery.²²

With any cosmetic injection, good technique is critical to success. During this study, material was placed into the deep dermal and subcutaneous space using serial puncture and retrograde linear threading. Care was taken not to inject the product into the superficial dermis, where it could become visible. Unwanted spread of the product was avoided by injecting small amounts and manually molding it after injection for the best final contour. Patients tolerate the molding well and should be cautioned to protect the treatment area from trauma or pressure in the post-treatment period.

The product is widely considered permanent because PMMA shows minimal biodegradation.²³ The presumed mechanism of action involves the bovine collagen carrier resorbing over time and replaced by collagenesis induced by the PMMA microspheres. Collagenesis in the nose seems to produce less volume than the original injection, thus multiple injection sessions are needed to produce the desired contour effect. Once a stable effect is produced, results lasts for at least 1 year and most likely will last much longer.

Dermal filling agents are used to repair defects arising after surgical rhinoplasty,²⁴ so patients with postrhinoplasty cosmetic defects were included. These contour irregularities are in different areas and require somewhat different correction techniques than those in unoperated patients.^{13,25} Nonsurgical rhinoplasty in postrhinoplasty patients demands advanced skills from the injector. Surgery causes scarring, unpredictable repositioning of blood vessels, and a more-tenuous blood supply. Risks of ischemia, necrosis, and vascular embolism are higher in these patients. Injectors must be conservative in the speed, force, and amount they inject.

Conclusions

This study demonstrates the safety and efficacy of a PMMA-based filler for nonsurgical rhinoplasty. Limitations include the small size of the study, no control group, and short duration, but the procedure has been performed in this clinic on an additional 500 or so patients with similar effectiveness and safety. The current protocol includes four touch-up injection sessions instead of two, with better contour correction and subject satisfaction.

Polymethylmethacrylate-injection rhinoplasty represents an important advance but does not replace surgery. Selected patients can avoid the pain, expense, risk, and downtime of traditional surgery. The physician must have a clear understanding of nasal anatomy and extensive injection expertise to minimize the incidence of complications. Longer follow-up of subjects is necessary to confirm prolonged duration and continued safety.

References

1. Survey from the American Society of Aesthetic Plastic Surgery 2011.
2. Cochran CS, Landecker A. Prevention and management of rhinoplasty complications. *Plast Reconstr Surg* 2008;122:60e–7e.
3. Advanced Aesthetics. Trends in Plastic Surgery Show the Growth of Non-Surgical Procedures. *Medical News Today* 2011.
4. Hanke CW, Robinson JK. Injectable collagen implants. *Arch Dermatol* 1983;119:533–4.
5. Glicenstein J. The first “fillers,” vaseline and paraffin From miracle to disaster. *Ann Chir Plast Esthet* 2007;52:157–61.
6. Feldmann H. History of injections. Pictures from the history of otorhinolaryngology highlighted by exhibits of the German History of Medicine Museum in Ingolstadt. *Laryngorhinootologie* 2000;79:239–46.
7. Rokhsar C, Ciocon DH. Nonsurgical rhinoplasty: an evaluation of injectable calcium hydroxylapatite filler for nasal contouring. *Dermatol Surg* 2008;34:944–6.
8. Monreal J. Fat grafting to the nose: personal experience with 36 patients. *Aesthetic Plast Surg* 2011;35:916–22.
9. Cassuto D. The use of Dermicol-P35 dermal filler for nonsurgical rhinoplasty. *Aesthet Surg J* 2009;29(3 Suppl):S22–4.
10. Lowe NJ, Maxwell CA, Patnaik R. Adverse reactions to dermal fillers: review. *Dermatol Surg* 2005;2:1616–25.

11. Glogau RG, Bank D, Brandt F, Cox SE, et al. A randomized, evaluator-blinded, controlled study of the effectiveness and safety of small gel particle hyaluronic acid for lip augmentation. *Dermatol Surg* 2012;2:1180–92.
12. Dayan SH, Greene RM, Chambers AA. Long-lasting injectable implant* for correcting cosmetic nasal deformities. *Ear Nose Throat J* 2007;86:25–6.
13. Stupak HD, Moulthrop TH, Wheatley P, Tauman AV, et al. Calcium hydroxylapatite gel (Radiesse) injection for the correction of postrhinoplasty contour deficiencies and asymmetries. *Arch Facial Plast Surg* 2007;9:130–6.
14. DiMaio FR. The science of bone cement: a historical review. *Orthopedics* 2002;25:1399–407 quiz 1408–9.
15. Cohen SR, Berner CF, Busso M, Clopton P, et al. Five-year safety and efficacy of a novel polymethylmethacrylate aesthetic soft tissue filler for the correction of nasolabial folds. *Dermatol Surg* 2007;33(Suppl 2):S222–30.
16. Piacquadro D, Smith S, Anderson R. A comparison of commercially available polymethylmethacrylate-based soft tissue fillers. *Dermatol Surg* 2008;34(Suppl 1):S48–52.
17. Artefill Instructions for Use 2010.
18. Artefill Skn Test—Instructions for Use 2010.
19. Springer IN, Zernio O, Nolke F, Warnke PH, et al. Gender and nasal shape: measures for rhinoplasty. *Plast Reconstr Surg* 2008;121:629–37.
20. Pawar SS, Garcia GJ, Kimbell JS, Rhee JS. Objective measures in aesthetic and functional nasal surgery: perspectives on nasal form and function. *Facial Plast Surg* 2010;26:320–7.
21. Lazzeri D, Agostini T, Figus M, Nardi M, et al. Blindness following cosmetic injections of the face. *Plast Reconstr Surg* 2012;129:995–1012.
22. Roberts SA, Arthurs BP. Severe visual loss and orbital infarction following periorbital aesthetic poly-(L)-lactic acid (PLLA) injection. *Ophthal Plast Reconstr Surg* 2012;28:e68–70.
23. Broder KW, Cohen SR. ArteFill: a permanent skin filler. *Expert Rev Med Devices* 2006;3:281–9.
24. Webster RC, Hamdan US, Gaunt JM, Fuleihan NS, et al. Rhinoplastic revisions with injectable silicone. *Arch Otolaryngol Head Neck Surg* 1986;112:269–76.
25. Paun SH, Nolst TG. Revision rhinoplasty: an overview of deformities and techniques. *Facial Plast Surg* 2008;24:271–87.

Address correspondence and reprint requests to:
 Alexander Rivkin, MD, Division of Dermatology,
 Department of Medicine, David Geffen School of
 Medicine, University of California at Los Angeles, 11645
 Wilshire Blvd, Los Angeles, California 90025, or e-mail:
 rivkinplastics@gmail.com